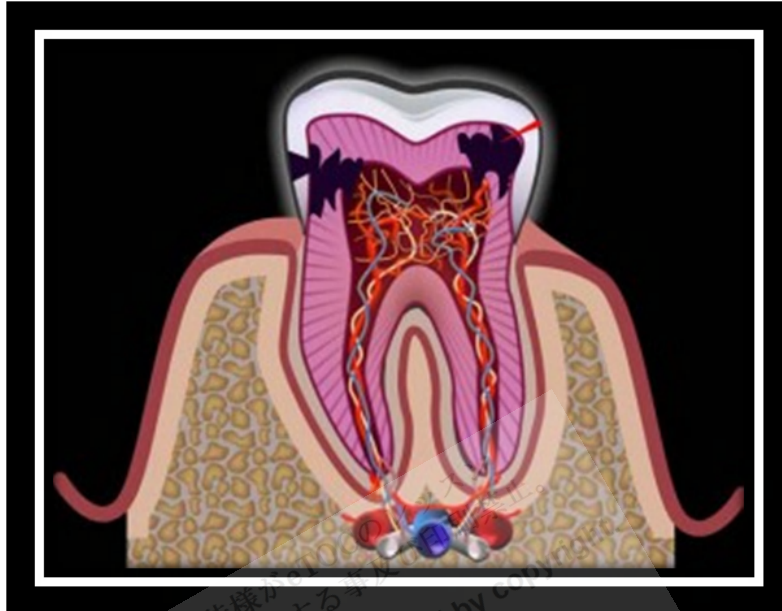


# Pulpitis



<http://www.checkdent.net/dental-blog/wp-content/uploads/2011/01/pulpitis-300x225.jpg>

*Pulpitis is inflammation of the dental pulp resulting from untreated caries, trauma, or multiple restorations. Its principal symptom is pain. Diagnosis is based on clinical findings and is confirmed by x-ray. Treatment involves removing decay, restoring the damaged tooth, and sometimes doing root canal therapy or extracting the tooth.*

Pulpitis can occur when

- Caries progresses deeply into the dentin
- A tooth requires multiple invasive procedures
- **Trauma** disrupts the **lymphatic** and blood supply to the pulp

Pulpitis begins as a reversible condition in which the tooth can be saved by a simple filling. It becomes irreversible as swelling inside the rigid encasement of the dentin compromises circulation, making the pulp necrotic, which predisposes to infection.

**Complications:** Infectious **sequelae** of pulpitis include apical **periodontitis**, **periapical abscess**, **cellulitis**, and **osteomyelitis** of the jaw. Spread from **maxillary teeth** may cause **purulent sinusitis**, **meningitis**, **brain abscess**, **orbital cellulitis**, and cavernous sinus thrombosis. Spread from mandibular

teeth may cause **Ludwig angina**, **parapharyngeal abscess**, **mediastinitis**, **pericarditis**, **empyema**, and **jugular thrombophlebitis**.

### **Symptoms and Signs**

In **reversible pulpitis**, pain occurs when a stimulus (usually cold or sweet) is applied to the tooth. When the stimulus is removed, the pain ceases within 1 to 2 sec.



<http://dentalcarematters.com/wp-content/uploads/Sensitive-teeth-300x199.jpg>

In **irreversible pulpitis**, pain occurs spontaneously or lingers minutes after the stimulus is removed. A patient may have difficulty locating the tooth from which the pain originates, even confusing the maxillary and mandibular arches (but not the left and right sides of the mouth). The pain may then cease for several days because of **pulpal necrosis**. As infection develops and extends through the apical foramen, the tooth becomes exquisitely sensitive to pressure and percussion. A **periapical (dentoalveolar)** abscess elevates the tooth from its socket and feels "high" when the patient bites down.

### **Diagnosis**

- Clinical evaluation
- Sometimes dental x-rays

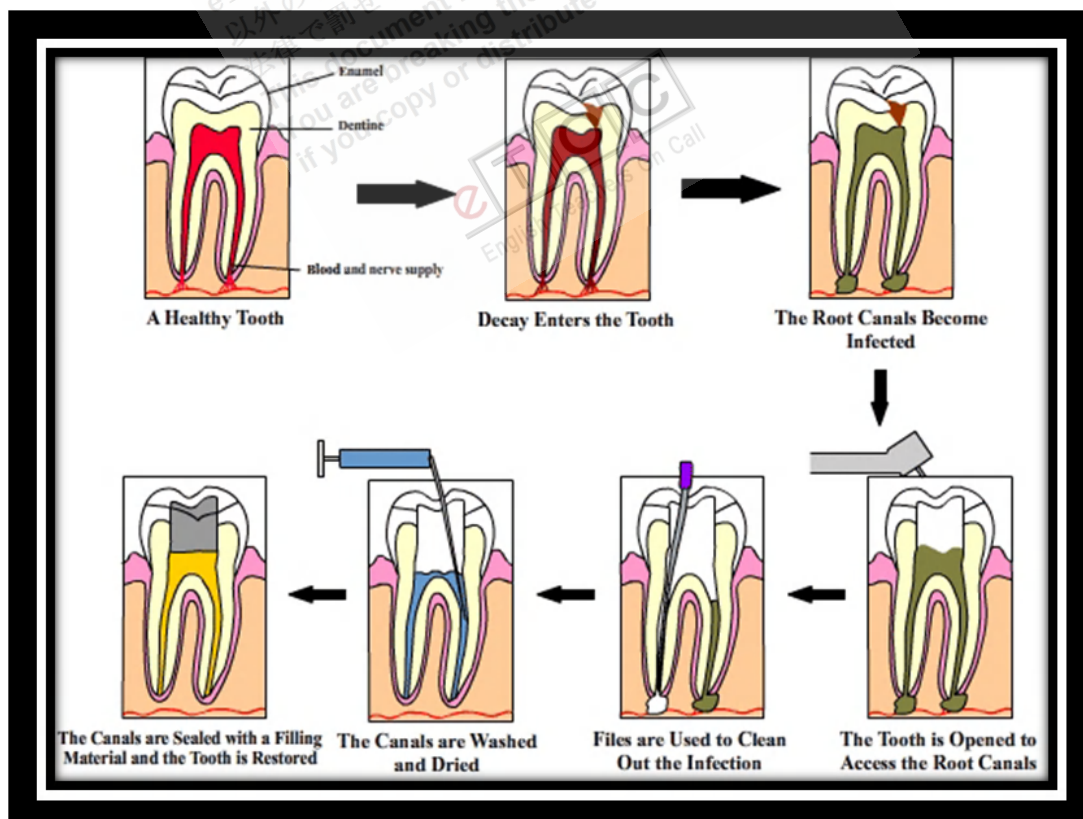
Diagnosis is based on the history and physical examination, which makes use of provoking stimuli (application of heat, cold, and/or percussion). X-rays help determine whether inflammation has extended beyond the tooth apex and help exclude other conditions.

### **Treatment**

- Drilling and filling for reversible pulpitis
- Root canal and crown or extraction for irreversible pulpitis
- **Antibiotics** (eg, **amoxicillin**) for infection

In **reversible pulpitis**, pulp vitality can be maintained if the tooth is treated, usually by caries removal, and then restored.

In **irreversible pulpitis**, the pulpitis and its **sequelae** require endodontic (root canal) therapy or tooth extraction. In endodontic therapy, an opening is made in the tooth and the pulp is removed. The root canal system is thoroughly debrided, shaped, and then filled with **gutta-percha**. After root canal therapy, adequate healing is manifested clinically by resolution of symptoms and **radiographically** by bone filling in the **radiolucent** area at the **root apex** over a period of months. If patients have systemic signs of infection (eg, fever), an oral antibiotic is prescribed (amoxicillin 500 mg q 8 h; for patients allergic to **penicillin**, **clindamycin** 150 mg or 300 mg q 6 h). If symptoms persist or worsen, root canal therapy is usually repeated in case a root canal was missed, but alternative diagnoses (eg, **temporomandibular disorder**, **occult tooth fracture**, **neurologic disorder**) should be considered.



<http://www.intelligentdental.com/wp-content/uploads/2010/09/new-1-root-cannak-trtmt.gif>

Very rarely, **subcutaneous** or **mediastinal** emphysema develops after **compressed air** or a **high-speed air turbine** dental drill has been used during root canal therapy or extraction. These devices can force air into the tissues around the tooth socket that dissects along **fascial planes**. Acute onset of jaw and **cervical swelling** with characteristic **crepitus** of the swollen skin on **palpation** is diagnostic. Treatment usually is not required, although **prophylactic antibiotics** are sometimes given.

### Key Points

- Pulpitis is inflammation of the dental pulp due to deep cavities, trauma, or extensive dental repair.
- Sometimes infection develops (eg, **periapical abscess**, **cellulitis**, **osteomyelitis**).
- Pulpitis may be reversible or irreversible.
- In reversible pulpitis, the pulp is not necrotic, a cold or sweet stimulus causes pain that typically lasts 1 or 2 sec, and repair requires only drilling and filling.
- In irreversible pulpitis, the pulp is necrotic, a cold or sweet stimulus causes pain that typically lasts minutes, and root canal or extraction is needed.

**Reference:** <http://www.merckmanuals.com>